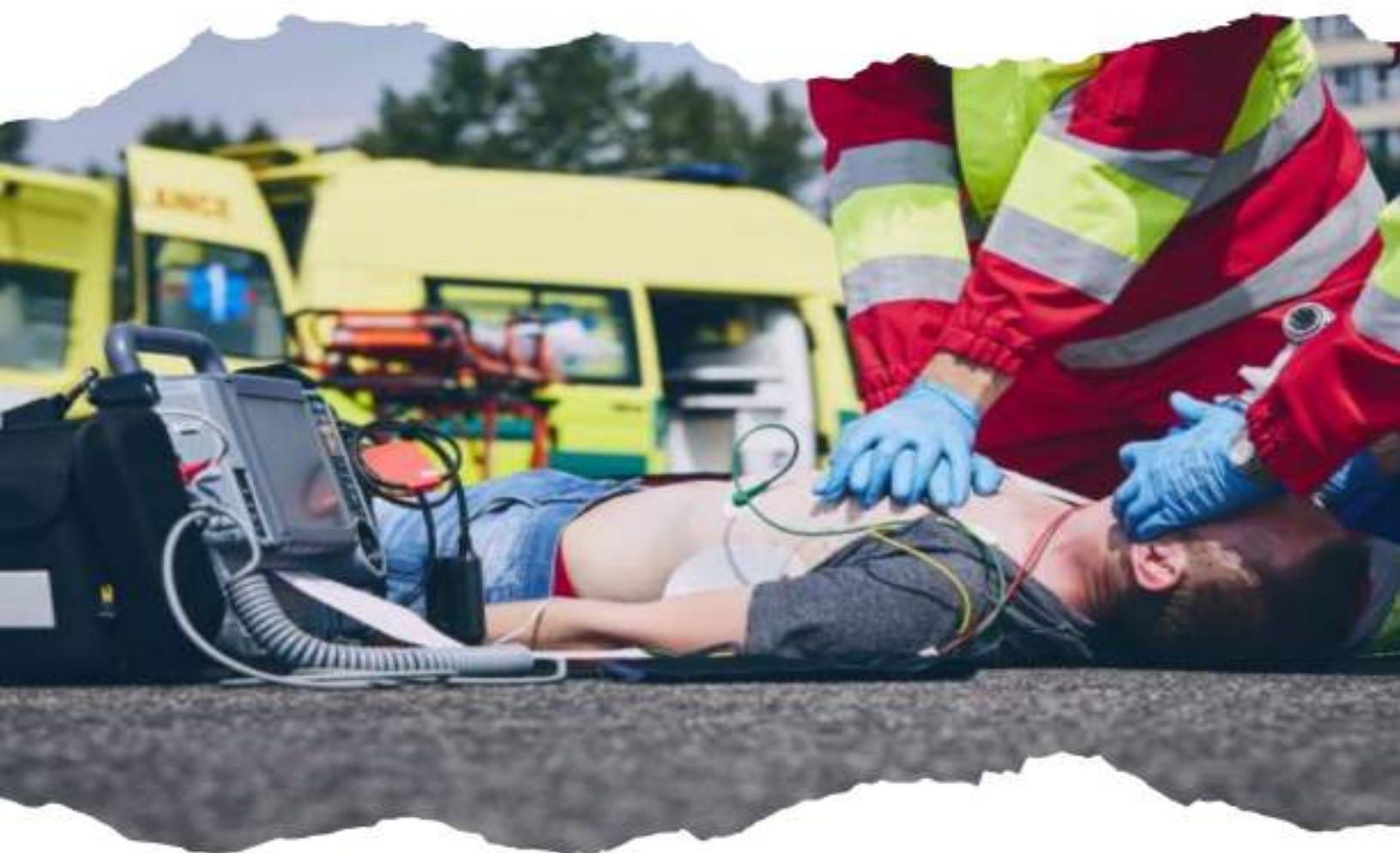

# **Provision of Airway Patency and Emergency intubation at the Prehospital Level**



**Ashyrbaev A.A. & Konokbai Murasbek  
2025**

УДК 616.2  
ББК 55.142  
А 98

**Рекомендовано учебно-методическим советом Университета  
АДАМ**

Рецензент: Толбашиева Г.У - к.м.н, доцент кафедры  
Анестезиологии и Интенсивной Терапии до и после дипломного  
обучения КГМА им. Ахунбаева И.А

А 98 Авторы: Аширбаев.А , Конокбай Мурасбек  
“Provision of Airway Patency and Emergency Intubation at the  
Prehospital Level” В ; 2025 - Р .

**ISBN 978-9967-476-81-3**

Данная книга предназначена для студентов старших курсов и ординаторов. В ней изложены основные методы оказания первой помощи при нарушениях дыхательных путей, включая технику интубации в условиях догоспитального этапа. Книга может служить полезным пособием для подготовки к экзаменам так же для практической деятельности

This book is intended for senior students and medical residents. It outlines the main methods of providing first aid in cases of airway obstruction, including intubation techniques in pre-hospital settings. The book can serve as a useful guide both for exam preparation and for practical application.

УДК 616.2  
ББК 55.142  
А 98

**ISBN 978-9967-476-81-3**

# PREFACE

This book is designed to provide a comprehensive understanding of airway management, covering both fundamental principles and advanced techniques. It aims to equip healthcare providers with the knowledge and practical skills necessary to handle airway emergencies effectively. Emphasizing both traditional and modern approaches, the book discusses various airway management tools and methods, ensuring that readers are prepared for real-world scenarios.

The objective of this work is not only to educate but also to bridge the gap between theory and practice. By offering clear, step-by-step guidance, this book serves as a valuable resource for medical students, residents, and practicing clinicians. The ultimate goal is to enhance patient safety and improve outcomes by promoting effective and timely airway intervention in emergency and critical care settings.

---

## Top Contributors

**Dr. Usama Illyas**

My Esteemed Student MD (General Medicine)



# **TABLE OF CONTENTS**

**01 INTRODUCTION**

**02 BRIEF ANATOMY OF THE UPPER RESPIRATORY TRACT**

**03 METHODS OF ENSURING PATENCY OF THE UPPER RESPIRATORY TRACT**

**04 TEMPORARY METHODS OF THE MAINTENANCE OF THE PATENCY OF URT**

**05 MAINTAINING PATENCY OF THE AIRWAY IN SPECIAL CIRCUMSTANCES**

**06 PERMANENT METHODS OF MAINTAINING PATENCY OF THE UPPER AIRWAY**

**07 ADDITIONAL EQUIPMENT USED TO PROVIDE THE PATENCY OF THE AIRWAY MONITORING**

**08 EMERGENCY OROTRACHEAL INTUBATION AT THE PREHOSPITAL LEVEL**

**09 CONCLUSION**

**10 TEST QUESTIONS**

## Introduction

Maintaining the patency of the upper respiratory tract (URT) in unconscious patients is the most important task for all specialists working in the field of critical care medicine. These are anesthesiologists-resuscitators, surgeons, doctors, paramedics and emergency nurses, rescue service workers and disaster medicine workers.

Every medical specialist working in the critical medicine, regardless of his profile and specialization, must be able to ensure the patency of the patient's airways in the most effective way.

In an unconscious patient, there is always a real risk of airway obstruction and death. The most common cause of airway obstruction in such patients is loss of muscle tone in the pharynx and tongue and obstruction of the airway. Airway obstruction with the patient's own tongue and foreign bodies, including saliva, blood, vomit, etc., is the most common cause of death that can be prevented.

It seemed that with the introduction of the tracheal intubation method using an endotracheal tube (ETT) into clinical practice, the problem of maintaining the patency of the upper respiratory tract in unconscious patients was solved. However, recently in developed countries new devices have been introduced into widespread clinical practice - a laryngeal mask, a combitube, and i-gel. Unfortunately, at present, these devices are not well known to a wide range of health workers in the Kyrgyz Republic. One of the goals of this work is to fill this gap.

The presented work is divided into two parts. The first part of the manual describes traditional methods of maintaining the patency of the upper respiratory tract in unconscious patients: using an oral and nasal airway and the Safar maneuver. Step-by-step instructions are given for using the "recovery position", conicotomy and the Heimlich maneuver when a foreign body enters the

respiratory tract. The first part also provides a detailed description of the laryngeal mask, combitube, and i-gel, which are already widely used in many countries today.

The second part of the tutorial provides a detailed description of the features of the method of tracheal intubation using ETT at the pre-hospital level, which has its own significant features from the hospital level.

The textbook is written in accordance with the working program of the academic discipline "Anesthesiology, Resuscitation, Intensive Care". It covers almost the entire scope of manipulations required in case of obstruction of the upper respiratory tract and covers in detail all issues of emergency orotracheal intubation at the prehospital level, which both a novice specialist and an experienced doctor may encounter in their professional work.

At the end of the work, control questions on the material covered, a list of recommended literature and Internet resources on this topic are offered. This tutorial can be recommended for students of medical schools, residents and general practitioners.

## Section 1

### Brief anatomy of the upper respiratory tract

The respiratory tract can be divided into two sections: upper and lower. The conventional boundary between them is the larynx. In our teaching and methodological recommendation, we will mainly talk about the upper respiratory tract (URT). These include the nose and its sinuses, tongue, pharynx, larynx and glottis(Figure 1).

The external nose is a protruding triangular pyramidal structure in the central part of the face. Its structure includes the root, the back, the apex, and two wings. The "skeleton" of the external nose is formed by the nasal bones and the frontal processes of the upper jaw, as well as a number of cartilages. The root of the nose has a cartilaginous base and creates limiting openings - the nostrils. The nose is covered with skin on the outside. Inside, the nostrils pass into a cavity called the vestibule of the nasal cavity.

The nasal cavity opens in front with the nostrils, and behind it communicates with the nasopharynx through openings - choanae. There are four walls in the nasal cavity: upper, lower and lateral. The nasal septum is located along the midline. There are three nasal conchae in the nasal cavity - upper, middle and lower. Under each nasal concha are located the upper, middle and lower nasal passages, respectively. Between the lateral edge of the nasal conchae and the nasal septum is the common nasal passage. The walls of the nasal cavity are covered with a mucous membrane.

The paranasal sinuses are cavities in the bones of the skull, lined with a mucous membrane and filled with air. They communicate with the nasal cavities through small canals. The paranasal sinuses are; the maxillary sinus, located in the body of the upper jaw; the frontal sinus, located in the frontal bone; the sphenoid

sinus, located in the body of the sphenoid bone; the cells of the ethmoid labyrinth, located in the ethmoid bone.

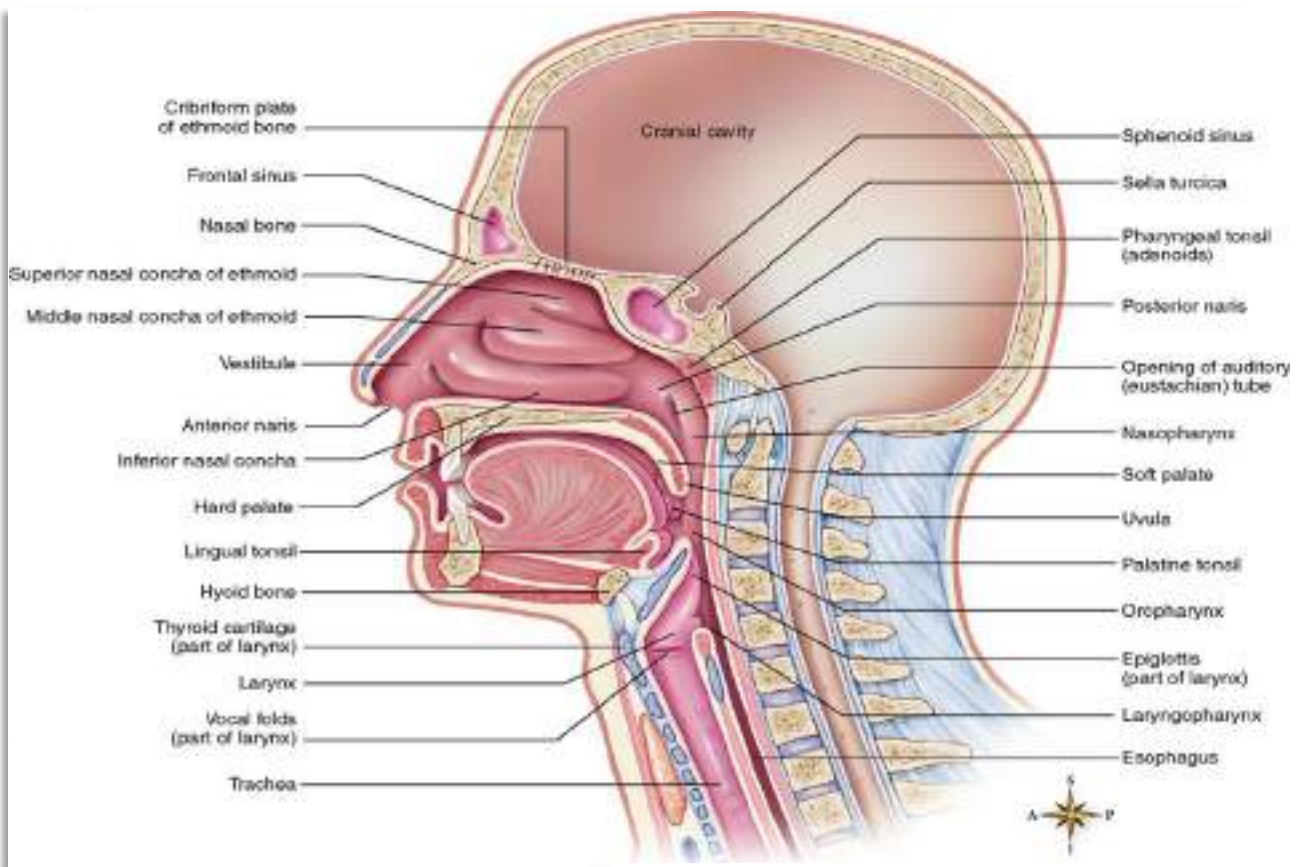
The tongue is a muscular organ that has a body and a root. The body is the largest part of the tongue, and it faces forward. The root attaches the tongue to the lower jaw and the hyoid bone. The surface of the tongue is covered with papillae.

The pharynx is a part of the digestive tract and respiratory tract, which is a connecting link between the nasal cavity and oral cavity on one side and the esophagus with the larynx on the other side. It extends from the base of the skull to the 6th-7th cervical vertebrae. The pharynx is divided into three parts: the nasal part, the oral part and the laryngeal part. The nasal part is a purely respiratory section. The oral part is the middle section of the pharynx. In front, it communicates with the oral cavity through the pharynx, its back wall is at the level of the third cervical vertebra. This part of the pharynx is a mixed section. Here, the digestive and respiratory tracts are united. The laryngeal part of the pharynx or laryngopharynx is its lower section. The entrance to the larynx and the entrance to the esophagus are located here.

The larynx is in the anterior region of the neck. At the top, it is connected to the hyoid bone by ligaments, and at the bottom, it continues into the trachea. The upper border of the larynx is located at the level of the intervertebral disc between the 4th-5th cervical vertebrae. The lower border of the larynx is located at the level of the 7th cervical vertebra. The larynx is covered by the muscles of the neck in front. The pharynx is located behind the larynx. In front of the entrance to the larynx, there is a cartilaginous formation - the epiglottis. When the epiglottis is lifted, the entrance to the larynx is visible, limited in front by the posterior surface of the epiglottis, behind - by the tops of the arytenoid cartilages and on the sides by the arytenoepiglottic folds.

The larynx cavity is divided into three sections: the upper section is the vestibule of the larynx, the middle section is the intermediate part of the larynx, and the lower section is the subglottic part of the larynx. The boundaries between the sections are the paired vestibular and vocal folds, which form the glottis.

Glottis is the boundary between the upper and lower respiratory tract. The glottis is about 25 mm long. It is in the middle part of the larynx. The glottis is limited by two vocal folds and the medial surfaces of the arytenoid cartilages. When the vocal cords vibrate, the size of the larynx changes. Below the vocal cords, the larynx passes into the trachea.



**Figure 1. Anatomy of the Upper Respiratory Tract.**

## Section 2

# Methods of providing patency of the upper respiratory tract

Methods of ensuring patency of the upper respiratory tract can be divided into temporary and permanent. Table 1. Methods of the provision of the patency of the upper respiratory tract (URT).

Temporary methods of maintaining airway patency include the triple Safar maneuver, oropharyngeal airway insertion, and nasopharyngeal airway insertion. These methods are temporary and cannot be used for a long time. They should be replaced with permanent methods as soon as possible, if necessary.

Permanent methods of providing the patency of the URT includes insertion of the endotracheal tube into the trachea, insertion of the supraglottic airways (laryngeal mask or I-Gel), and insertion of a combitube.

Within the framework of the program "Basics of Life Support", in the first part of this teaching and methodological manual (TMM) only temporary methods of providing patency of the URT will be considered. Specifically, these methods include "Safar's Triple Maneuver", "Insertion of the oropharyngeal airway", "Insertion of the nasopharyngeal airway".

In addition to these methods, maintenance of the patency of the URT in special circumstances will be described: "Recovery position" and "Heimlich maneuver". The latter maneuver is used when a foreign body enters the respiratory tract in adults. Measures that are used when a foreign body enters the respiratory tract in children and cricothyrotomy (needle cricothyrotomy) will be considered too.

Permanent methods of providing the patency of the URT, namely the introduction of supraglottic airways (laryngeal mask, Ai-Jel) and the introduction of a combitube are not included in the program of "Basics of Life Support", therefore in this material they will be described briefly. In addition, it should be said that these devices are not widely used in the Kyrgyz Republic for many reasons, such as lack of supply, high price, etc.

The second part of this teaching material will consider tracheal intubation using an endotracheal tube (ETT) at the prehospital level. It is the "gold standard" and it is used as the most common and effective method for the definitive provision of the patency of URT. Due to historical tradition, the endotracheal airway is often called an endotracheal tube, so we will further adhere to the same terminology.

Table 1

## Methods of provision of the patency of the upper respiratory tract

	<b>Temporary provision of airway patency of the URT</b>	<b>Definitive maintenance of patency of the URT</b>
1.	Safar's Triple Maneuver	1. Insertion of an endotracheal tube (ETT) into the trachea
2.	Insertion of the oropharyngeal airway (OPA)	2. Insertion of supraglottic airways (laryngeal mask, I-Gel)
3.	Insertion of the nasopharyngeal airway (NPA)	3. Insertion of the combitube into the larynx/esophagus.
		4. Cricothyrotomy (needle cricothyrotomy)
	<b>Provision of the airway patency under special circumstances</b>	
1.	Providing recovery position	
2.	Heimlich maneuver for foreign body obstruction of the URT	

## Section 3

# Temporary provision of airway patency of the URT

### 3.1 Safar's Triple maneuver

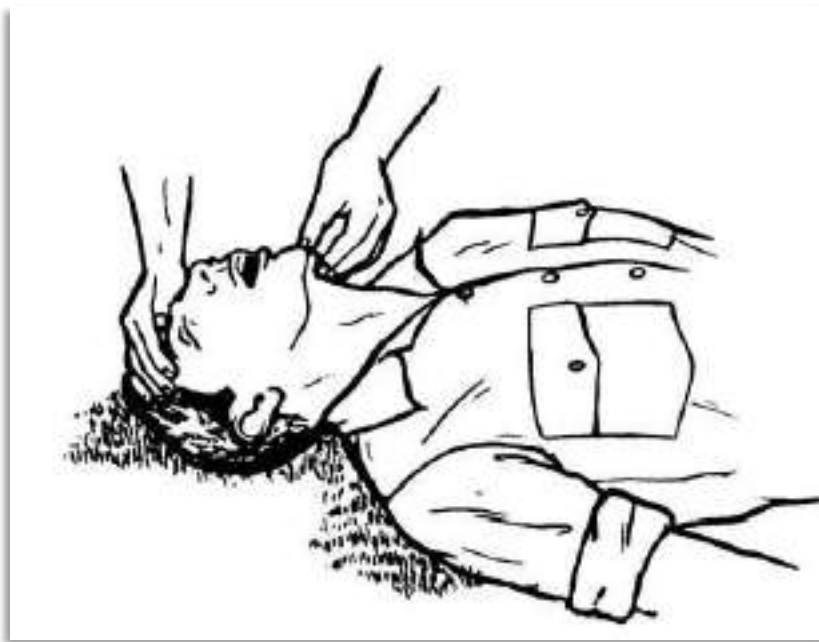
As mentioned earlier, an unconscious patient has a risk of airway obstruction and death. The most common cause of airway obstruction in such patients is loss of tone in the pharynx and tongue muscles and their obstruction of the airways. Airway obstruction with the tongue and foreign bodies, such as saliva, blood, vomit, etc., is the most common cause of death that can be prevented.

Safar proposed a triple maneuver, which consists of three actions: head tilt, chin lift and open mouth. When performing these three actions, the tongue is moved forward, and the airways will be opened. Since the second half of the twentieth century, Safar's triple maneuver has become a mandatory technique for medical professionals and for non-professionals after short courses of training in rescue actions.

There are several nuances that a rescuer needs to know. Firstly, the Safar maneuver is performed only when the victim is in supine position. It is necessary to loosen everything that is on the chest and prevent free breathing: clothes need to be unbuttoned, belts and fasteners loosened. If there are removable dentures, they must be removed. The person must be put on a hard surface, the easiest on the floor or ground. In winter, it is advisable to put a blanket under it, if there is one and time allows.

### Step-by-step technique for performing the triple Safar maneuver:

1. The rescuer is positioned to the side of the victim at the level of his head.
2. The palm of the rescuer's firsthand is placed on the victim's forehead.
3. Two fingers (second and third) of the rescuer's second hand are placed under the victim's chin.
4. The thumb of the rescuer's second hand is placed on the victim's chin. Thus, with three fingers of the second hand, the rescuer grasps the victim's chin. Performing simultaneous movement, perform head tilt, chin lift and open mouth (Figure 3).



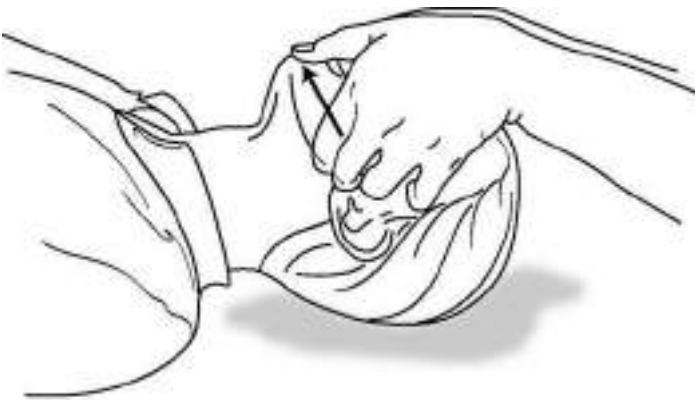
**Figure 3. Safar's Triple maneuver**

It should be noted that if the victim is suspected of having a cervical spine injury, the triple Safar maneuver must not be performed. Any movement of the neck may worsen the condition. In this case, a double maneuver may be used: only pushing the jaw forward and opening the mouth. If it is not possible to open the mouth completely, the tongue is simply held out by hand. Airways or other

resuscitation equipment can be used. Cervical spine injury may be suspected in three conditions: a change in the level of consciousness, the presence of damage above the collarbone, and multiple trauma (Figure 4).

**Step-by-step technique for performing a double take:**

1. The rescuer is positioned at the head of the victim. Sometimes it is possible to place the patient's head between the rescuer's knees.
2. Both thumbs of the rescuer are placed in the "dog hole" area on both sides.
3. The second, third and fourth fingers of both hands are placed on the corners of the mandible. The mandible moves forward, and the mouth opens.



**Figure 4. Moving forward the mandible and opening the mouth**

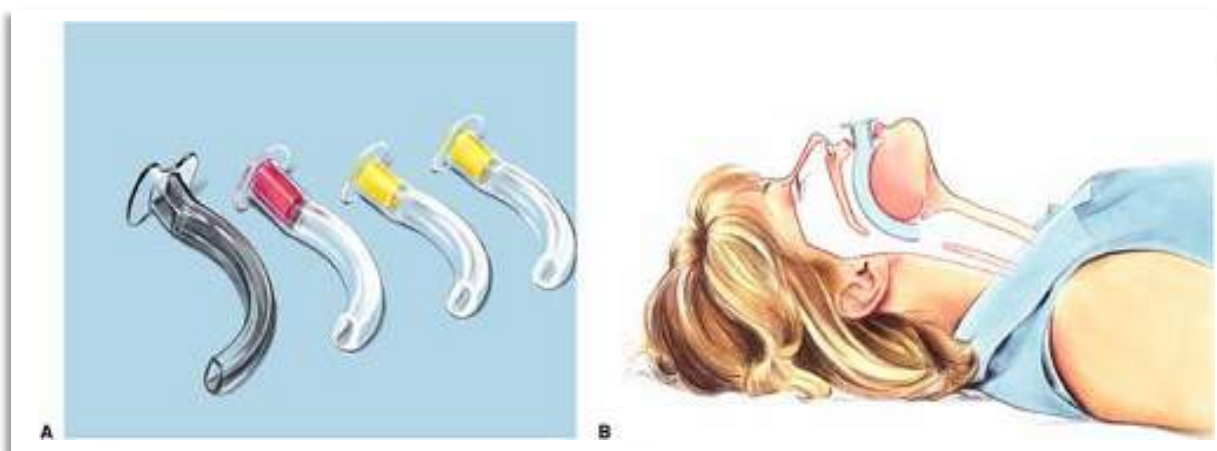
### Section 3.2 Airways insertion

The insertion of airways allows temporary maintenance of airway patency, but each of them has indications and contraindications. Airways are made of plastic. They can be reused after appropriate cleaning. There is no advantage of one type of airway over another. The advantages or disadvantages of each of them depend on the situation.

#### Oropharyngeal airway (OPA)

The insertion of the OPA is performed only in an unconscious patient and in the absence of reflexes from the URT. Otherwise, the insertion of the OPA may cause laryngospasm and gag reflex. This is highly undesirable in patients with a full stomach. Such patients can be seen at the pre-hospital level, when they are provided with medical aid on the street (Figure 5).

**Figure 5. OPA and its location in the URT.**



### Step-by-step technique for inserting an OPA

1. Open the victim's mouth and clear the oral cavity and pharynx of secretions, blood, and vomit using your fingers or a suction device with catheter, if possible.
2. The correct size of oral airway must be selected. To determine the correct size, place the OPA on the side of the face. One end of the OPA should be at the corner of the mouth, the other end of the OPA should be at the corner of the lower jaw. When the OPA is selected correctly, its distal end will be above the opening of the pharynx.
3. The OPA must be inserted in such a way that its concave part is initially located in the direction of the hard palate.
4. Once the OPA has passed through the oral cavity and reached the back wall of the pharynx, it should be rotated 180 degrees and continue until it is positioned properly. The main purpose of this manipulation is to ensure that the concave part of the oral airway follows the contour of the tongue. The tongue, in turn, should not be accidentally displaced backwards towards the pharynx and does not block the airway.

There is an alternative method of inserting the OPA. Take a spatula and press the tongue. Then insert the OPA so that its concave part is in the direction of the tongue. Move the OPA until it takes the good position.

After the insertion of the OPA, the patient must be monitored. The patient's head and neck must be held in such a way as to maintain the patency of the airway.

### **Possible adverse effects when inserting an oral airway:**

- An OPA that is too large may obstruct the larynx or cause injury to the larynx or its structures.
- An OPA that is too small, it can push the tongue back into the pharynx and the tongue can block the airway.
- Insertion of the OPA must be done carefully to avoid injury to the soft tissues of the oral cavity and lips.
- It is important to remember that OPA can only be inserted in unconscious patients, who have no cough and pharyngeal reflexes, otherwise the OPA may stimulate cough, vomiting and laryngospasm.

### **Insertion of a nasopharyngeal airway (NPA)**

An NPA is used as an alternative to an OPA in patients who also require airway management. It is an uncuffed soft plastic tube that allows air to pass freely from the nasal openings to the pharynx (Figure 6).

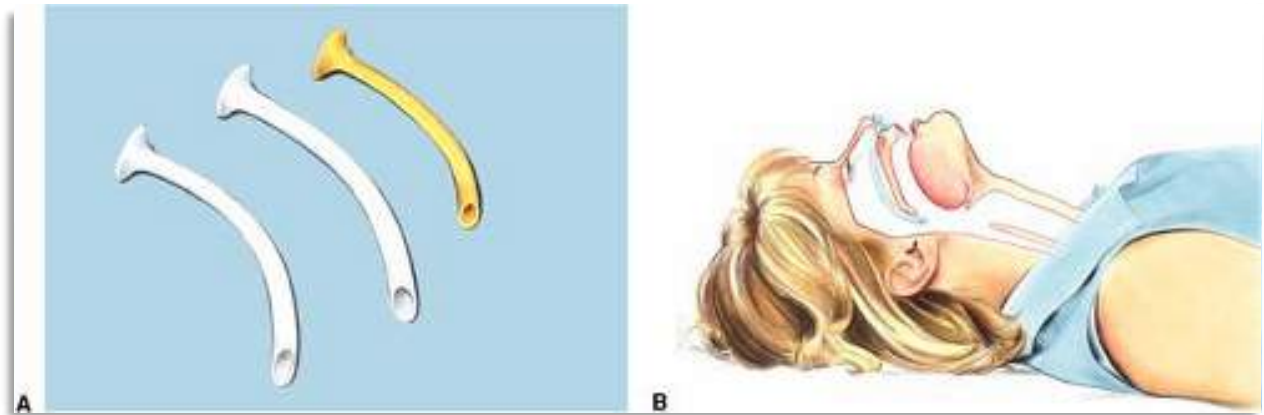
Unlike the OPA, the NPA can be used in conscious or semi-conscious patients, i.e. in patients with preserved cough and pharyngeal reflexes. The NPA is indicated in cases where insertion of the OPA is contraindicated, technically difficult or dangerous. Such cases may occur with poor mouth opening, loose teeth, facial and oral trauma, trismus of the muscles, in patients with orthodontic devices, the application of metal wires to the jaws, as well as with preserved cough and pharyngeal reflexes.

A NPA may also be used in patients with neurological disorders who have bad coordination and tone of the pharyngeal muscles, leading to airway obstruction.

### **Step-by-step technique for inserting a NPA**

1. It is necessary to select the correct size of the NPA. To determine the required size of the NPA, place it on the side of the face. One end of the NPA should be at the wing of the nose, the other end of the NPA should reach the earlobe. When the NPA is correctly selected, its distal end will be above the opening of the pharynx.
2. The correct diameter of the NPA must be selected. To do this, compare the outer circumference of the nasal airway with the inner diameter of the nasal opening. The NPA should not be too large in diameter, to stretch the nasal opening. Some rescuers use the diameter of the patient's little finger as a guide to select the correct size of the NPA.
3. Before inserting the NPA, it is necessary to lubricate the nasal airway and the airway itself with a water-soluble lubricant.
4. Insert the NPA through the nostril. The insertion process should be in the posterior direction perpendicular to the plane of the face. It is necessary to move the airway forward very carefully along with the back wall of the nasopharynx.
5. If resistance is felt during insertion of the NPA, the following steps should be done slightly rotate the NPA to further advance it or try to insert the NPA through a second nostril.

**Figure 6. Position of the NPA in the URT**



**Precautions when using a NPA:**

- Care must be taken when inserting the NPA to avoid complications. The NPA may damage the mucous membrane of the nasal cavity, damage the nasal passages, cause bleeding, and cause blood clots to enter the trachea. In these cases, aspiration of blood and secretions using a suction device will be necessary.
- Too long NPA can enter the esophagus. Later, when performing ventilation, for example with a breathing bag and mask, air may enter the stomach.
- Too long NPA may cause laryngospasm and vomiting, even if it is well tolerated by semi-conscious patients.
- NPA is relatively contraindicated in patients who are taking anticoagulants, in patients with nasal infections and nasal deformities due to the risk of bleeding.
- In patients with basal skull fracture, the use of a NPA is contraindicated because it may enter the cranial cavity through a fractured cribriform plate.

### **General precautions when using OPA and NPA:**

- It is always necessary to check for spontaneous breathing immediately after the insertion of both airways.
- The patient's condition must be assessed continuously. Maintain head tilt with the jaw thrust technique using the chin lift or jaw thrust technique. Some secretions such as mucus, blood, and vomiting may obstruct the distal part of the airway. In these cases, frequent suctioning of these secretions from the URT may be necessary to ensure patency of them.
- If ventilation is absent or inadequate, positive pressure ventilation should be initiated immediately.
- If there is no equipment for ventilation (for example, a breathing bag), it is necessary to use the mouth-to-mouth, mouth-to-nose, or mouth-to-mask ventilation methods.

## Section 4

# Maintaining patency of the airway under special circumstances

### 4.1 Recovery position

The recovery position was first described by Dr. Robert Bowles in England in 1881. He described the position for patients with epilepsy, but later anesthetist Frederick Hewitt of the London Hospital suggested using this position for patients in anesthetic practice. This idea was not widely used in surgery. Even many years after this suggestion, surgical textbooks advised to put patients in supine position.

First aid organizations such as the British Red Cross wrote in their first aid manuals in the 1940s that a person should be on his back, face up, throat in a straight line. It was only in the 1950s when they began to point out that an unconscious patient should be placed in the recovery position.

Although the recovery position was widely used in Europe in the 1950s, the American Heart Association adopted the recovery position in their guidelines in 1992.

Indications for placing the patient in the recovery position are unconsciousness with preserved breathing to reduce the risk of airway obstruction with the tongue, saliva, blood or vomit. Such situations may occur in patients with alcohol or drug intoxication.


The recovery position is also used as a temporary measure while waiting for an ambulance, when transporting patients with decreased level

of consciousness, and other cases. When necessary, consider switching to the provision of airway patency using the OPA or NPA.

### **Step-by-step technique for placing the patient in the recovery position**

1. Kneel at the patient's side, straighten both of the patient's legs.
2. Place the patient's first arm, which is closest to you, at a right angle to the patient's torso. The patient's arm should be bent at the elbow, with the palm facing up.
3. Pull the patient's second arm, which is farthest from you, across the patient's chest and place the back of the hand under the patient's cheek, which is closer to you.
4. Using your other hand, bend the knee of the patient's lower limb that is farthest from you at a right angle.
5. Pull the patient towards you with the shoulder and knee at the same time and turn the patient onto his side.
6. Fix this position by placing the leg on top at a right angle (Figure 7).

**Figure 7. Recovery position**



## 4.2 URT obstruction and Heimlich maneuver

Obstruction of the URT due to food or water is a life-threatening condition. Such a patient can die quickly if he does not receive immediate help. URT obstruction usually occurs due to the following reasons: swallowing food in large portions or pieces; eating and drinking while doing some activities, such as playing sports; talking and laughing while eating and drinking; constantly having a foreign body in the mouth, such as chewing gum or candy.

In the above cases, the obstruction of the URT may be complete or partial. Accordingly, with partial obstruction, some air will pass through the URT. This will be accompanied with coughing, respiratory noise, inspiratory dyspnea, cyanosis of the skin, lips and face.

In case of complete obstruction of the URT, there will be no air passage through them. The patient will not be able to speak and will cough intensely. In both types of obstruction, the patient will keep both hands crossed over the throat, which is a universal sign of URT obstruction.

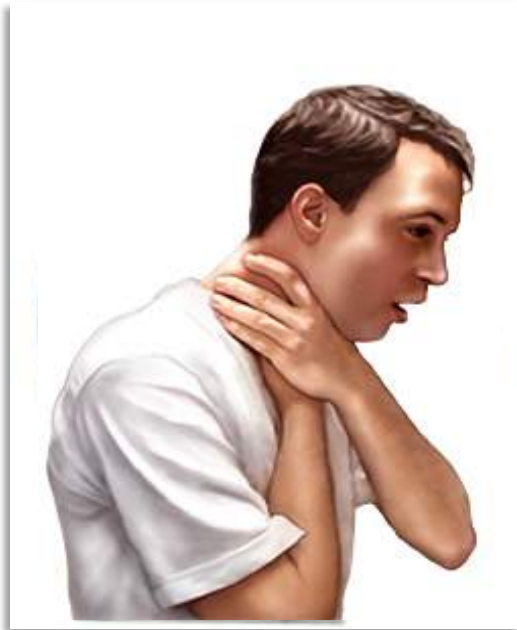


Figure 8. Universal sign of the obstruction of the URT.

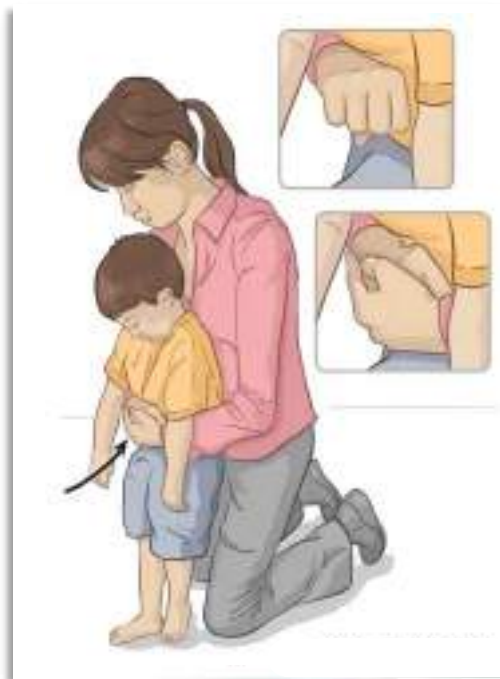### **First steps when a foreign body lodged in the URT.**

1. If there is partial obstruction of the URT, the victim should be encouraged to cough up the foreign body.
2. If attempts to cough up the foreign body are unsuccessful, the rescuer must deliver five blows with the palm of the hand on the back between the shoulder blades of the victim.
3. If this manipulation also proves unsuccessful, it is necessary to perform the Heimlich maneuver.

### **Step-by-step technique of the Heimlich maneuver for adults and adolescents:**

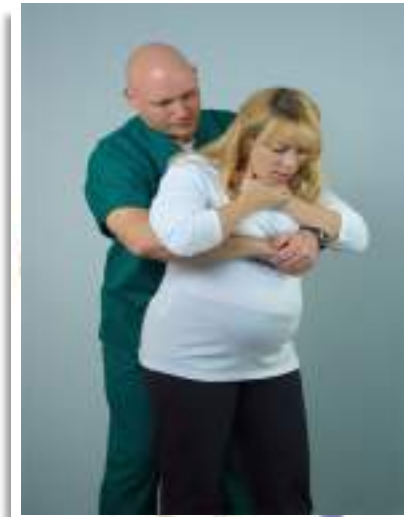1. Stand behind the patient and place your arms around the patient's waist. Make a fist with one hand.

2. Place this fist on the abdomen between the navel and the xiphoid process of the sternum.
3. Grasp your fist with your other hand and make several sharp movements (thrusts) in the above-mentioned abdominal area. The direction of the thrusts should be backwards and upwards (Figure 9).
4. Repeat these movements in this area of the abdomen until the foreign body comes out of the airway.
5. If the foreign body does not come out from the airway and the patient loses consciousness, begin CPR.



**Figure 9. Heimlich maneuver technique for teenagers**

If the victim is a pregnant woman or a patient with a large belly, then these people need to perform the Heimlich maneuver in the chest area.



**Figure 10. Heimlich maneuver for a pregnant woman**

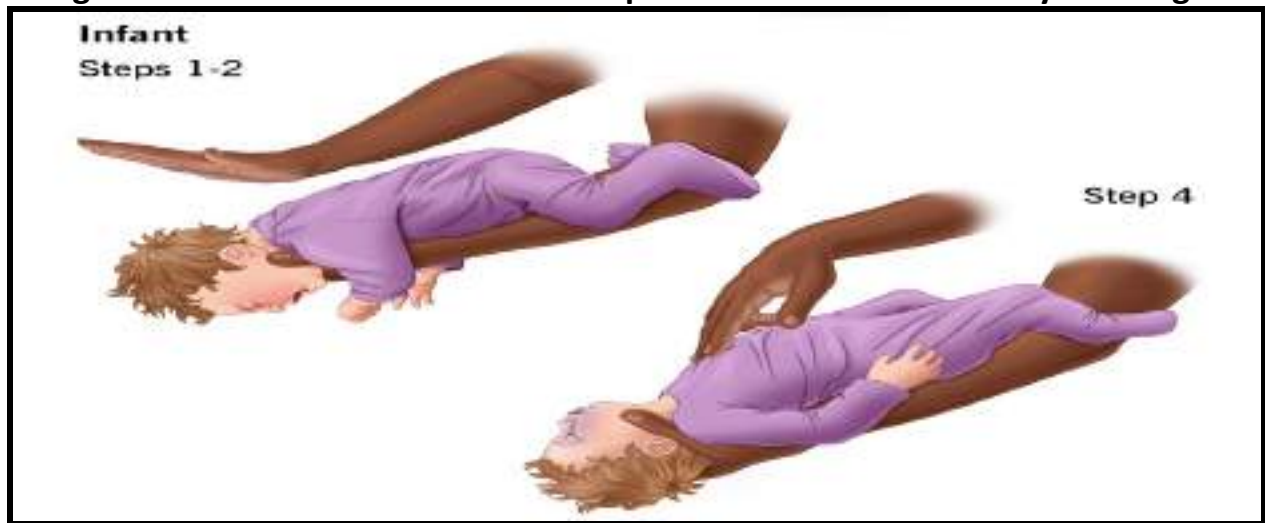
In children, the obstruction of the URT occurs mainly due to small objects that small children put in their mouths. The Heimlich maneuver for children under one year of age differs from that for adults for several reasons. Firstly, the abdominal organs of small children are not covered by the ribs, so trauma to the soft organs of the abdominal cavity is possible with sharp pressure on the abdomen.

Therefore, the pushes are not performed in the abdominal area, but on a harder part of the child's body - on the sternum. Secondly, the child's weight allows you to pick him up and perform all actions on the rescuer's lap. It is advisable to clean the oral cavity first. It is not recommended to clean the child's oral cavity blindly, since it can push the foreign body further into the larynx.

### **Step-by-step technique for the Heimlich maneuver for children under one year of age**

1. Sit on a chair and hold the baby on your laps.
2. If time and circumstances permit, remove the child's clothing.
3. Hold your baby face down on your forearms so that his head is slightly lower than his chest. Support the baby's head and lower jaw with your hand. Be careful not to put pressure on the soft tissue of the baby's neck. Place your hands on your knees or thighs to support the baby.
4. Use your palm to deliver five strong blows to the child's back between the shoulder blades. The blows should be strong enough to dislodge the foreign body from the airway.
5. If the foreign body has not come out of the airway after five strong blows with your palm, place your hand on the child's back. A child of this age should fit easily on your forearms. Your one hand should support the child's face and mandible, and your other hand should support the child's back.
6. Turn the baby as one unit, supporting the baby's neck and head. Place your hands on your knee or thigh to support the baby. Hold the baby face up so that his head is lower than his body.
7. Perform five thrusts in the mid-chest area, at the bottom of the sternum. The thrusts should be strong enough to dislodge the object from the airway. Continue alternating five strong blows to the back with five thrusts in the mid-chest area until the object is dislodged. If your efforts are unsuccessful and the child loses consciousness, begin CPR (Figure 11).

**Figure 11. Heimlich maneuver technique for children under one year of age**



### **4.3 Cricothyrotomy (needle cricothyrotomy)**

Cricothyrotomy is an invasive procedure that involves a median incision of the cricothyroid ligament of the larynx between the cricoid and thyroid cartilages. There is a discrepancy in terminology due to the old name of the ligament between the cricoid and thyroid cartilages. Previously, this ligament was called the conical ligament, so the dissection of this ligament was called a coniotomy or coniotomy.

Cricothyrotomy should be performed in an emergency when you fail to restore the patency of the URT using all the above methods (Safar's maneuver, Heimlich's maneuver, etc.). In such a situation, there is a real threat of respiratory arrest and death of the victim. Any doctor must be able to perform cricothyrotomy. The cricothyrotomy kit should be in the standard equipment list of the resuscitation bag and in the standard equipment list of the anesthesiology and resuscitation

department. Currently, there are factory-made sterile cricothyrotomy kits from different companies. However, sometimes cricothyrotomy should be performed at the prehospital level using improvise tools. Such tools can be a kitchen knife and drinking straw.

Cricothyrotomy is a safer method than tracheotomy. First, the cricothyroid membrane is located directly under the skin. Second, there are no large vessels or nerves in this area. Third, this manipulation is relatively easy to perform, unlike tracheotomy, which is usually performed by an experienced doctor.

Needle cricothyrotomy is a type of cricothyrotomy. It involves puncturing the cricothyroid ligament with the largest needle. At the prehospital level, the largest 14G intravenous catheter can be used for this purpose. The catheter is first used to puncture the skin and cricothyroid ligament. After passing the cricothyroid ligament, the catheter is tilted at the angle of 60 degrees and advanced distally for few centimeters. The steel needle is then removed, leaving the catheter in place. It is possible to use two catheters simultaneously to increase the diameter.

Thus, needle cricothyrotomy partially restores airway patency. It is obvious that this method does not fully provide oxygenation of the victim. However, this manipulation can buy time to deliver the patient to a medical facility (Figure 12).

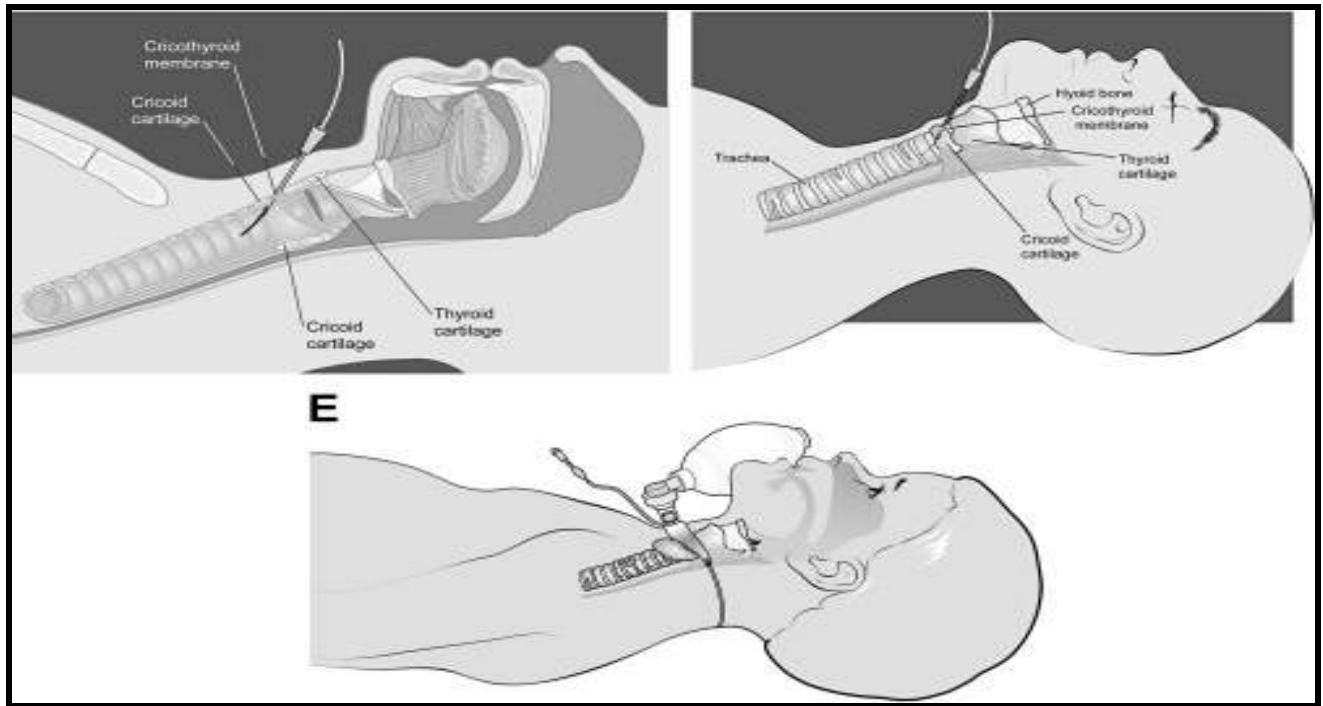


Figure 12. Needle cricothyrotomy

## Section 5

# Definitive methods of providing the patency of the URT

### 5.1 Supraglottic airways: Laryngeal mask and i-Gel.

In 1980, Archie Brown from Great Britain created the laryngeal mask (LM), which reduced the overall number of tracheal intubations. The use of LM became an important step in the development of maintaining the patency of the URT. Currently, several types of LM are used, including the i-Gel.

The LM and I-Gel are supraglottic airway devices. The LM and I-Gel are inserted blindly through the mouth (i.e. without the use of a laryngoscope) and are positioned above the larynx. The LM and I-Gel ensure continuous airway patency (Figure 13).

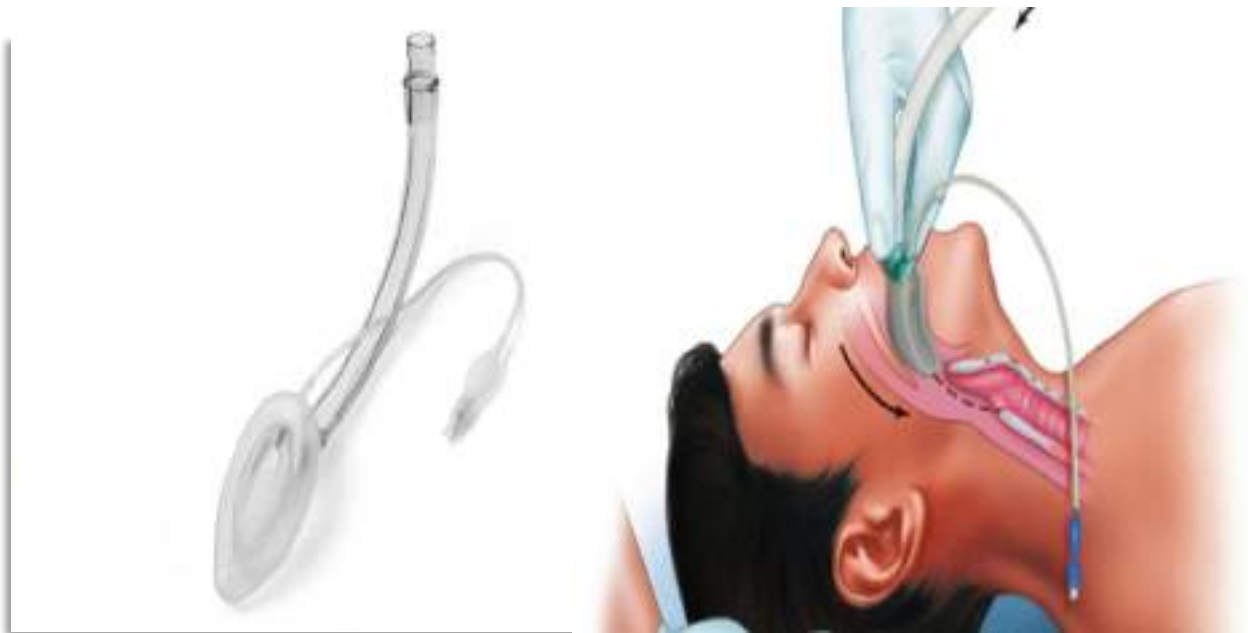Both devices have a tube and a cuff. The LM has several differences from the I-Gel. The first difference is that the LM cuff is inflated through a cannula, just like the ETT. The I-Gel cuff is made of soft plastic and does not need to be inflated. The second difference is that the I-Gel tube has a wider ellipsoid cross-section in the middle part, which makes it more stable. The third difference is that the I-Gel has a reinforced internal structure at the level of the patient's incisors. This prevents damage to the lumen of the tube in case of biting. Both devices have a channel for the esophageal tube.

Mechanical ventilation can be performed through the LM and I-Gel. Both devices are used in elective surgery for short operations and in situations where tracheal intubation is impossible. The disadvantages of both devices are that they do not always provide sufficient seal of the airways. Therefore, the threat of aspiration of gastric contents is not fully prevented.

LM and I-Gel are not intended for emergency surgery and sometimes, if improperly inserted, they can lead to airway obstruction due to the folding of the epiglottis. This complication can occur in 10% of patients. In such cases, these devices should be removed and re-inserted. In European countries, LM and i-Gel are widely used at the hospital level in elective surgery for short operations.

In most cases, LM and I-Gel are for single use. There are also devices that can be reused after appropriate cleaning. There are sizes for children and adults.

**Figure 13. Laryngeal mask and its location above the larynx**



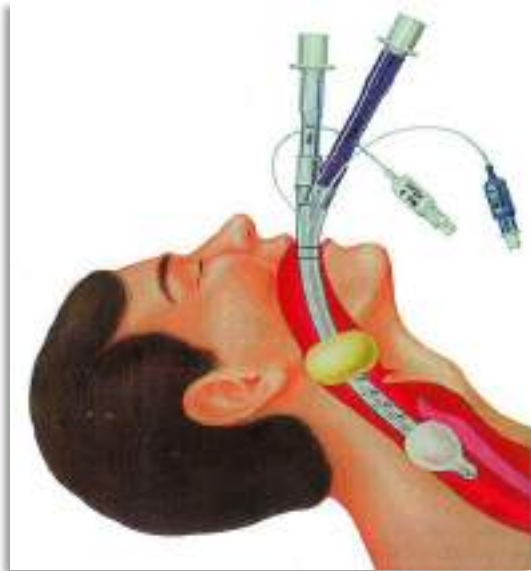
## 5.2 Combitube

The combitube is designed to ensure airway patency in difficult and urgent situations. It is a double-lumen tube with two cuffs to create a seal and protect the airways. It is necessary for emergency intubation and effective ventilation of the lungs at the prehospital level, which includes paramedics, rescue teams and disaster medicine specialists (Figure 14).

Combitube is inserted blindly through the mouth (i.e. without the use of a laryngoscope). A large cuff creates a seal and provides stability of the Combitube. Unlike traditional tubes, the Combitube is made to ensure airway patency and ventilation of the lungs regardless of whether the tube enters the esophagus or trachea.

The principle of using the combitube is as follows: when the Combitube is inserted blindly, it enters the esophagus "by default". The "esophageal" lumen (the longer blue tube) has a closed end. When the cuff on the esophageal end of the combitube is inflated, it seals the esophagus, protecting the airways from aspiration of gastric contents. Above the esophageal lumen, there are eight lateral ventilation holes. Above them is the second cuff. When it is inflated, the "tracheal" lumen of the combitube is sealed.

In some European countries, the combitube is widely used at the pre-hospital level, where paramedics work in ambulances and do not have much experience in tracheal intubation. It should be noted that the combitube can also be used in hospital settings when difficult tracheal intubation is expected. The combitube is not used in Kyrgyzstan for many reasons.



**Figure 14. Combitube and its location in the esophagus and above the larynx**

### 5.3 Endotracheal tube with cuff

**Endotracheal tube** (ETT) is a high-tech device designed to maintain the airway patency at all times. When properly sized and inserted into the trachea, an ETT with an inflated cuff ensures complete airway sealing. The risk of gastric contents aspiration into the lungs is minimal. An introducer is usually used with the ETT, which allows to shape the ETT during intubation when inserted into the trachea (Figure 15).

The ETT is one of the main tools of anesthesiologists, so it is important to understand the meaning of the markings that are applied to the surface of the ETT. The markings show the following information:

1. The size of the internal diameter in millimeters.
2. The size of the external diameter in millimeters.

3. Length of the tube in centimeters. In addition, along the entire length of the ETT there are marks of its length in centimeters. These marks allow you to find out to what length the tube is inserted.
4. Manufacturing company.
5. The material from which the tube is made.

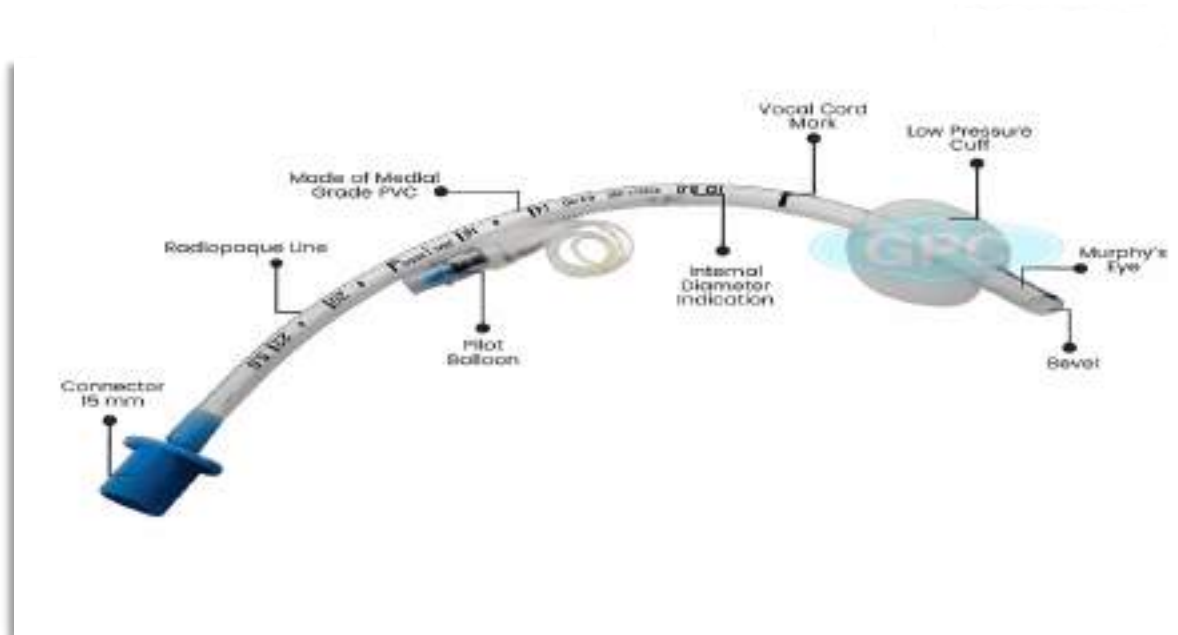
In addition, the ETT has several important devices:

1. Cuff (at the distal end of the tube) - when inflated, it secures the airways.
2. A control cylinder with a valve connected to the cuff serves to confirm the tightness of the cuff.
3. Murphy's eye - serves to ensure a continuous flow of the gas even if the distal end of the tube is obstructed.
4. Connector (at the proximal end of the tube) – allows the ETT to be connected to a breathing bag or a circuit of the lung ventilator.
5. Blue strip (radiopaque) – allows you to determine the location of the tube in the airways during an X-ray examination.

It should be noted that in addition to standard ETTs, there are special tubes for special cases. Within the framework of the program "Basics of Life Support", in this education materials the information about these tubes will have just an informative purpose. Special ETTs include:

1. Double lumen tube (Carlens's type) - used in thoracic surgery. These tubes are to be used to ventilate the left and right lungs separately.
2. S-shaped and reinforced tubes (Rush type) - are used in maxillofacial surgery. These tubes do not change the diameter of the lumen when they are bent or changed in configuration.
3. Children's tubes - used in pediatric surgery. These have no cuff, since in children the lumen of the trachea is very narrow and in addition they have a physiological narrowing of the trachea.

Figure 15. Endotracheal tube with cuff.



## Section 6

### **Additional equipment used to provide the patency of the airway. Monitoring**

When talking about basic provision of airway patency, it is necessary to mention additional equipment. Its presence is absolutely necessary in the arsenal of specialists working in the field of critical medicine. This equipment includes:

- Vacuum suction device (electrical or mechanical).
- Suction catheters (soft Nelaton catheter, rigid Jankauer catheter).

#### **Suctioning of the respiratory tract.**

Suctioning the airway is a necessary component to maintain airway patency. If there is blood, secretions or vomiting in the airway, the rescuer must immediately remove these bad substances with suction device to prevent their aspiration.

#### **Two types of suction devices: portable suction devices and stationary suction devices.**

- Portable suction devices are used in places where there is no power supply and/or where patient transportation is possible. Such situations may be outdoors or in an ambulance. Portable suction units are small and usually fit into medical bags. These suction units are mechanical and operate using a hand or foot pump. There are also portable electric suction units which work using a car cigarette lighter. They create a slight negative pressure (from -80 to -120 mm Hg). Sometimes this pressure may be insufficient in certain situations, for example, if the oral secretions are very thick (Figure 16).

- Stationary suction units are usually used in hospitals. They are either on rollers or fixed to the wall. Such suction units create a large negative pressure (up to -300 mm Hg).



**Figure 16. Portable suction**

### **Suction Catheters**

There are two types of suction catheters: soft and hard.

- Nelaton soft catheters can be used in the patient's mouth and nasal passages. They are usually supplied in soft, sterile packages. Soft catheters can also be used to suck secretions from the ETT.
- Rigid catheters (Jankauer catheters) can be used either in the oral cavity or deep in the pharyngeal space. Such catheters can be used to suck thick mucus, secretions, or solid particles (Figure 17).

### **Step-by-step technique for suctioning contents from the URT.**

Suction from the oral cavity using a soft catheter should be performed in the following sequence:

- Carefully insert the catheter into the oral cavity above the tongue.
- Suck out mucus and secretions by closing the side opening with your finger while simultaneously pulling out the catheter and simultaneously rotating the catheter.
- If you are using a rigid catheter (Jankauer catheter), place the end of the catheter in the oral cavity. Advance it further into the oropharynx until you reach the oropharynx.

### **Step-by-step technique for performing suction of contents from the ETT:**

Some patients with pulmonary secretions may require ETT suctioning even after tracheal intubation. Suctioning of mucus and secretions from the ETT using a soft catheter should be performed in the following sequence:

1. Use only a sterile catheter to avoid contamination of the lower respiratory tract.
2. Carefully insert the catheter into the ETT. Ensure that the side opening of the catheter is not obstructed during advancement of the catheter. Insertion of the catheter beyond the distal end of the tube is not recommended as this may cause damage to the tracheal mucosa or stimulate coughing and bronchospasm.
3. Perform airway suction by closing the side opening with a finger and simultaneously pulling out the catheter, while simultaneously rotating the catheter. The suction procedure should not exceed ten seconds. In order to avoid hypoxia, the patient must be oxygenated with oxygen before and after the airway suction procedure.

### Monitoring during the procedure.

During the airway clearance procedure, it is always necessary to monitor vital signs: heart rate, pulse, blood oxygen saturation, and clinical observation. If the patient develops bradycardia, blood oxygen saturation decreases, and the patient's condition worsens, the procedure must be stopped immediately. High concentration of oxygen must be administered until the heart rate returns to normal and the patient's condition improves. Assisted ventilation must be performed as indicated.

**Figure 17 Types of catheters: rigid Jankauer catheter and soft Nelaton catheter**



## Section 7

# Emergency orotracheal intubation at the prehospital level

In this section, the term "healthcare worker" will be used instead of "rescuer". This emphasizes the need for tracheal intubation to be performed only by trained health care personnel. The objectives of this chapter are to:

- To determine indications for orotracheal intubation at the prehospital level.
- To highlight potential problems associated with orotracheal intubation in the prehospital setting.
- To outline ways to correct possible problems associated with orotracheal intubation.
- Describe tracheal intubation using the rapid sequence intubation method.

Tracheal intubation with ETT is a "gold standard" in maintaining the patency of the upper airway. In the hospital, i.e. at the in-hospital stage, it is a fairly routine procedure. However, at the pre-hospital stage, tracheal intubation with ETT should always be considered "difficult intubation". This is due to many factors. We will briefly list only a few of them:

- At the pre-hospital stage, safety of the scene is a problem. A medical worker cannot always control the surrounding environment. It often happens that he must work with a patient in a dangerous condition for him.
- Poor general lighting, such as darkness, may result in poor visualization of anatomical structures (larynx). This situation may be aggravated by an atypical or inconvenient positioning of the patient and the medical worker.
- An important feature of all patients at the pre-hospital stage is a "full stomach". In emergency pre-hospital care, the health worker often does

not have time to prepare the patient for tracheal intubation, in particular, gastric lavage before intubation. If the stomach contents get into the lungs, a formidable complication - acid aspiration pneumonitis - may develop.

- There may be a facial skeletal injury or multiple injuries to other organs.
- There are not enough assistants and there are always many people who interfere with work.
- Etc.

At the prehospital level, the main indication for tracheal intubation is signs of increasing cerebral, respiratory or cardiovascular failure, or most often all of them together. Such signs include:

1. From the side of the central nervous system: decreased level of consciousness. It can vary from confusion to coma.
2. From the cardiovascular system, these are sharp hemodynamic disorders: low blood oxygen saturation, low blood pressure, severe rhythm disturbances and cardiac arrest.
3. From the respiratory system, there can be two groups of conditions:
  - The patient cannot maintain airway patency: this may include existing or increasing airway obstruction because of a burn, edema, or infectious lesions of the respiratory tract.
  - In which the patient, despite the presence of spontaneous breathing and patency of the airways, cannot maintain sufficient ventilation or oxygenation. These are, as a rule, patients in critical condition with injuries, multisystem diseases or intoxications.

All patients show clinical signs of shock, severe central and peripheral cyanosis, pale skin, impaired hemodynamics, severe dyspnea, involvement of additional muscles in the breathing process, retraction of intercostal spaces, and absence of normal respiratory sounds during auscultation.

There are very few contraindications to emergency orotracheal intubation. Caution is always necessary when cervical spine injury is suspected. If this is a case, it is necessary that the patient's neck and head be immobilized with a cervical collar before performing tracheal intubation. In this situation, tracheal intubation is technically very difficult, but possible.

The number of possible medical problems and possible individual patient characteristics that can affect the outcome of tracheal intubation is very large. Therefore, we will list only a few of them. Complex intubation can be assumed in the following situations:

**Possible medical problems of the patient include:**

- Tumors of the neck and upper respiratory tract.
- Burns of the face and upper respiratory tract.
- Edema of the upper respiratory tract (e.g. angioedema, thermal edema).
- Inflammation and infection of the URT (e.g. epiglottitis).
- Obstruction of the airway with foreign bodies (e.g. vomit, blood, saliva, dentures).
- Traumatic injuries of the face, oral cavity, internal organs.
- Traumatic injuries of the cervical spine.

**Possible individual characteristics are:**

- A patient with a cervical collar applied to immobilize the cervical spine.
- Patients with protruding anterior incisors.
- Unusual anatomical position of the larynx - forward shift.
- A patient with a short, thick neck.
- A patient with an underdeveloped lower jaw.
- Patient with abnormal development of teeth (outside the arch).
- Patient with a big tongue.

- A patient with limited mobility of the lower jaw - ankylosis of the temporomandibular joint.

**The equipment required to perform rapid sequence intubation should include:**

- Heart monitor - connected.
- A blood pressure monitor, preferably automatic - connected.
- An intravenous catheter is installed, and the intravenous infusion system is connected.
- Oxygen cylinder - connected. Oxygen flow should be 6-7 liters/min.
- Pulse oximeter - connected.
- Capnography (exhaled air CO<sub>2</sub> detector) - connected.
- Breathing bag (Ambu bag) with masks of different sizes.
- A set of sterile ETTs of various sizes with cuffs and a guidewire. Each cuff should be checked for leaks before tracheal intubation.
- Laryngoscope with blades of different sizes and shapes. It is always necessary to check the laryngoscope before intubation.
- An additional light source is usually a flashlight.
- Suction (it is always necessary to check its operation before intubation) and suction catheters of different sizes: soft and hard.
- Gastric tubes (NG tubes) of different sizes.
- Syringes (5 and 10 ml) for inflating the ETT cuff.
- Water-soluble lubricant for lubricating ETT.
- Personal protective equipment (gloves, aprons, face mask or goggles).
- Airways of different sizes (OPA, NPA).
- Adhesive tape for fixation of ETT.
- Stethoscope to control the correct position of the ETT.
- A set of medications: fentanyl - painkillers; propofol, thiopental, ketamine - hypnotics; succinylcholine, atracurium - muscle relaxants; atropine, lidocaine - premedication agents.

- Towel – usually used to create an additional elevation under the head of at least 10 cm.

Special attention should be paid to the position of the health worker and the patient before performing orotracheal intubation. There may be situations when the patient is on a stretcher in the ambulance or on the ground. In the latter case, the health worker may be lying on his stomach, leaning on his elbows above the patient, or lying on his left side. In these situations, performing intubation is technically very difficult, but possible. The main condition for the health worker is the correct positioning of the patient for good visualization of the anatomical structures of the larynx.

#### **Step-by-step procedure for orotracheal intubation:**

1. It is necessary to check and make sure that all the listed equipment is present and that it all works. This is usually done in advance.
2. It is necessary to perform preoxygenation of the patient. It is very important for the entire procedure. Oxygenation is performed to ensure blood saturation with oxygen and to create a reserve of oxygen in the blood for tracheal intubation to avoid severe hypoxemia. If the patient is breathing, you should let him breathe 100% oxygen through a mask for a couple of minutes. If the patient is not breathing, you should give him 8-10 breaths using a breathing bag.
3. The administration of hypnotics, analgesics and short-acting muscle relaxants, to facilitate tracheal intubation is performed using the dosages specified in the Rapid Sequence Intubation (RSI) Protocol.
4. Insertion of the laryngoscope and visualization of the larynx with it is performed using standard techniques.
5. The placement of the ETT, coated with a water-soluble lubricant, between the vocal cords is performed using standard technique.
6. Confirmation of correct tube placement is accomplished by auscultation and capnography, and fixation of the ETT in place.

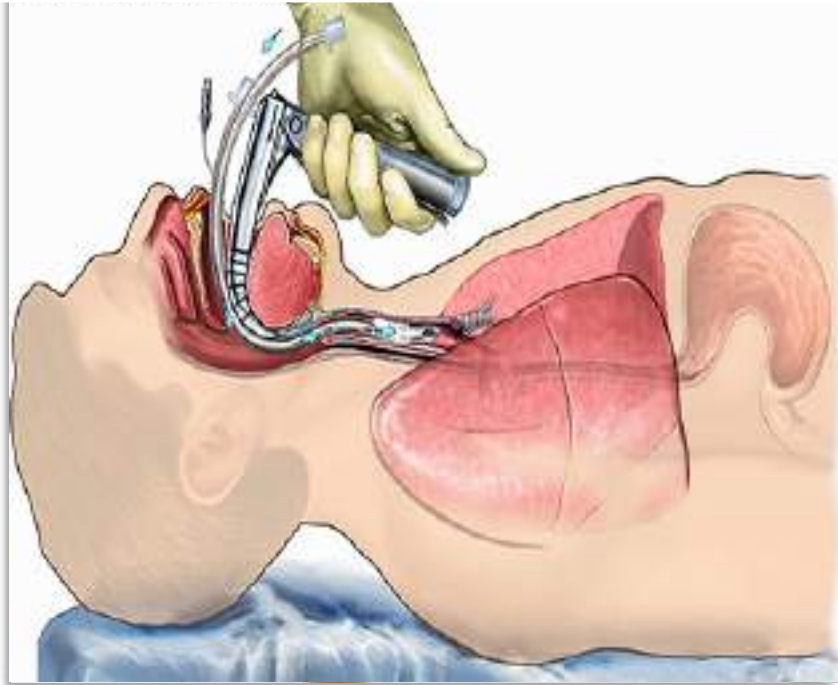
**Step-by-step technique for performing Rapid Sequence Intubation (The complete protocol of the BPI is presented in Table No. 2)**

- Take the laryngoscope in your left hand.
- Open the patient's mouth with your right hand.
- Have an assistant perform the Sellick maneuver (pressing on the patient's cricoid cartilage).
- Insert the laryngoscope and move the patient's tongue to the left.
- Advance the laryngoscope further toward the epiglottis.
- Once the epiglottis is visible, it is necessary to lift it with the tip of the blade of the laryngoscope.
- By pulling along the axis of the laryngoscope handle, examine the vocal cords (direction of traction - upward and forward).
- You should not lean on the patient's front teeth to avoid damaging them.
- Ask an assistant to hand over the ETT with the introducer in it.
- Under visual control, it is necessary to perform ETT between the vocal cords (Figure 18).
- Have an assistant inflating the ETT cuff using a 10 ml syringe. The usual cuff volume is 10 ml.

Table 2. Rapid Sequence Intubation Protocol

1. Preoxygenate the patient with 100% oxygen using a mask. If ventilatory support is required, provide it using a breathing bag.
2. Perform the Sellick maneuver (this should be done by an assistant) – pressure on the cricoid cartilage.
3. Premedicate the patient using the following medications:
  - Administer Atropine 0.5 mg in adults and 0.01 mg/kg in children and adolescents intravenously
  - Administer Fentanyl 2-3 mcg/kg intravenously
  - Administer Lidocaine 1.5-2.0 mg/kg intravenously slowly over 60 seconds
  - Administer Arduan 1 mg intravenously to precurarize the patient
4. Administer one of the following drugs to induce anesthesia: Sodium thiopental 3-5 mg/kg, Ketamine 2 mg/kg, Propofol 1.5-2.5 mg/kg.
5. Administer succinylcholine (syn. suxamethonium, dithiline) 1.5 mg/kg for complete paralysis of the body muscles.
6. Check for complete muscle relaxation: no breathing, lower jaw without tonus, decreased resistance in the lungs when breathing with a breathing bag.
7. Perform tracheal intubation. If you are unable to intubate the patient within 20 seconds, stop. Restart ventilatory support with a breathing bag.
8. If you are able to intubate the patient, inflate the cuff. Connect the patient to a ventilator or continue ventilation with a breathing bag.
9. Check capnography and listen to the breathing sounds in the lungs at six points and above the stomach.
10. Secure the ETT with tape.

**Figure 18. Tracheal intubation (side view)**



Immediately after performing the RSI, it is necessary to make sure that the ETT is positioned correctly. To do this, take a breathing bag and take several breaths. If the chest rises evenly on both sides, then the tracheal intubation has been performed correctly. Using a stethoscope, it is necessary to listen to the respiratory sounds in both lungs at six points and above the stomach. The golden rule of intubation is: "If in doubt about the location of the ETT, pull it out and try again"

Sometimes, if the ETT is inserted too deeply, it may end up in the right bronchus. This happens because the right bronchus is straight, while the left bronchus is at an angle. This situation can be corrected as follows. It is necessary to slightly pull the tube out, while listening to the respiratory sounds in the left lung. As soon as respiratory sounds appear in the left lung, you should stop pulling

out the tube. This usually happens at the 22 cm mark on the tube at the level of the upper incisors. It is necessary to hold the ETT in this position until it is secured with adhesive tape.

If there is a CO<sub>2</sub> sensor in exhaled air, it should be connected to the ETT. If the trachea is intubated correctly, there will be CO<sub>2</sub> coming from the lungs and the sensor will indicate this. After tracheal intubation, it is necessary to continue to ventilate the patient and constantly monitor his condition. The most common problems with tracheal intubation are presented in Table 3.

To solve problems during tracheal intubation, it is necessary to use common sense and simple methods:

- If you fail to intubate after one or two attempts, do not panic. Remember that the main goal is to oxygenate the patient.
- It is necessary to ventilate the patient with a breathing bag several times. When re-intubating, it is necessary to try to perform the Sellick maneuver - pressing on the cricoid cartilage backwards and upwards to see the glottis.
- If the patient is severely obese, he should be placed in a position with his head elevated, with a pillow placed under it.
- It is important to always have a "contingency plan" in mind in case of unsuccessful intubation.

**Table 3. The most common problems during tracheal intubation**

	The problem with intubation	Solution to the problem
1.	You see only the soft tissue of the esophagus.	The laryngoscope blade is inserted too deeply. Gently pull the blade back.
2.	You cannot lift the epiglottis.	The laryngoscope blade is too short, the blade needs to be changed.
3.	You only see the tongue.	The tongue is not pulled to the left enough. Pull the laryngoscope blade out and start again.
4.	Patients with short necks and obesity.	Raise the patient's head by placing a pillow under it.

If the patient has become worse after intubation, it is necessary to urgently eliminate the cause of this condition. To assess this condition, the SOPO mnemonic rule can be used:

- **S**uction with endotracheal tube placement
- **O-ABOUT** endotracheal tube obstruction
- **P**neumothorax

- **O – ABOUT** equipment failure

Your next actions will depend on what problem was detected. If the ETT is displaced, it is necessary to try to bring it into the correct position without attempting to re-intubate the trachea, although this possibility cannot be completely excluded. In case of obstruction of the ETT by a foreign body (mucus, blood, etc.), it will be necessary to try to remove the contents with suction device and restore tube patency. In this situation, re-intubation of the trachea may sometimes be necessary.

In case of pneumothorax, it will be necessary to urgently perform needle decompression of the pleural cavity on the side of the pneumothorax at the second intercostal space, at the midclavicular line.

If the equipment fails or there is no electrical power, it will be necessary to switch to manual ventilation with a breathing bag until the equipment is fixed or replaced with another one.

**Conclusion:**

The main key to patient safety in the prehospital level is the airway. Most cases of complications and subsequent deaths are due to unexpected problems with airway patency.

Every rescuer and medical worker, regardless of his specialization, must know temporary methods for providing the patient's airway patency. At the prehospital stage, this most often involves performing the Safar maneuver, performing the Heimlich maneuver, or giving the recovery position.

At the prehospital level, the main indication for tracheal intubation is a combination of cerebral, respiratory or cardiovascular failure. When making a decision on tracheal intubation, it is always necessary to remember that every prehospital intubation is a "difficult intubation".

Tracheal intubation with ETT is the "gold standard in providing patency of the upper airway". At the prehospital level, constant readiness for tracheal intubation is always necessary. Constant readiness means the readiness of medical equipment, medical drugs and a medical worker.

The patient does not die from failed intubation. The cause of death may be the failure of ventilation and oxygenation. If there is a risk of difficult intubation, then an algorithm of actions must be planned before intubation begins.

The golden rule of intubation is: "When in doubt about the location of the ETT, pull it out." Even with correctly performed tracheal intubation, it is always necessary to continuously monitor the position and patency of the ETT, as well as the general condition of the patient.

**Test questions on the topic (20 questions):**

1. The most common cause of upper airway obstruction in an unconscious patient is:
  - A. Secretion of salivary glands.
  - B. Foreign body.
  - B. Posterior displacement of the tongue.
  - G. Vomit.
  
2. If you witness a victim's airway obstruction caused by a foreign body (food particles) in a restaurant, your first step should be:
  - A. You must perform CPR.
  - B. You must call an ambulance by phone.
  - Q. You should perform a cricothyrotomy.
  - G. You should encourage the patient to cough, then deliver five blows to the back between the shoulder blades and, if these measures are unsuccessful, perform the Heimlich maneuver.
  
3. Temporary methods of maintaining patency of the upper airway include all of the following except:
  - A. Insertion of an OPA.
  - B. Safar's Triple maneuver.
  - B. Insertion of a NPA.
  - G. Insertion of the ETT with cuff.
  
4. On a warm summer day, you (a lifeguard or a medical worker) are walking through a park. You see an unconscious man lying on the grass. On primary survey, you find that his airway is clear, he is breathing 10 times per minute, but he is unconscious. There is a strong smell of alcohol on his breath. Your actions:

- A. Turn the person into the recovery position.
  - B. Turn the person onto his stomach.
  - B. Turn the person onto his back.
  - G. Place the person in a semi-sitting position.
5. The Laryngeal Mask and I-Gel belongs to:
- A. The supraglottic airways.
  - B. The endotracheal airways.
  - B. The NPA.
  - G. The OPA.
6. The most common cause of airway obstruction in a healthy person is:
- A. Swallowing food in large pieces.
  - B. Consuming food and liquids, especially alcohol, during physical activity
  - B. Talking and laughing while eating and drinking
  - G. All answers are correct.
7. What is the patient's body position in the "recovery position":
- A. The patient is on his side, and his oral cavity should be below the level of the trachea.
  - B. The patient is on his back, with his arms and legs wide apart.
  - B. The patient is on his stomach; his arms and legs should be brought close to the body.
  - G. The patient is in a semi-sitting position, his arms should be brought to the body, his legs should be wide apart.
8. To select the correct length of the OPA, put it at the side of the face:
- A. One end should be at the corner of the mouth, the other end should be at the corner of the lower jaw on the same side.

B. One end should be at the corner of the mouth, the other end should be at the protruding part of the thyroid cartilage.

B. One end should be at the corner of the mouth, the other end should be at the opening of the ear canal on the same side.

G. One end should be at the corner of the mouth, the other end should be at the outer corner of the eye on the same side.

9. What does the "golden rule of intubation" say:

A. If you have any doubts about the location of the ET tube, get a chest x-ray.

B. If you are in doubt about the location of the ET tube, remove it.

Q. If you have any doubts about the location of the ET tube, call the colleague.

G. If you doubt the location of the ET tube, then do nothing and leave everything as it is.

10. Insertion of an OPA in the patient in a semi-conscious state with preserved cough and pharyngeal reflexes may lead to the following consequences:

A. Cough and laryngospasm.

B. Vomiting and aspiration of stomach contents into the trachea and lungs.

B. Trismus of the masticatory muscles.

G. All answers are correct.

11. The execution of the triple Safar technique is as follows:

A. Head tilt, chin lift, open mouth.

B. Head tilt, chin lift, mechanical ventilation.

B. Head tilt, jaw thrust, CPR.

G. Head tilt, jaw thrust, insertion of the OPA.

12. Esophageal intubation may result in:

- A. Lack of ventilation of the lungs with subsequent hypoxia and death of the patient.
- B. Tension pneumothorax as a result of the damage of the visceral pleura and lung tissue.
- B. Air in the stomach can cause aspiration of the stomach contents into the lungs.
- G. Answers A and B are correct.

13. All statements regarding the NPA are true except:

- A. When inserting a NPA, bleeding may occur due to trauma to the nasal mucosa.
- B. It is possible that the NPA may enter the cranial cavity due to a fracture of the base of the skull.
- B. Too long NPA can cause coughing and laryngospasm.
- D. Insertion of an NPA is always preferable to the use of an OPA.

14. The reasons for difficult tracheal intubation at the prehospital level are:

- A. Nighttime and atypical patient position.
- B. Trauma to the patient's facial bones.
- B. Unfamiliar or hostile environment.
- G. The correct answers are A, B and C.

15. The needle cricothyrotomy performed at:

- A. In the area of the ligament between the hyoid bone and the thyroid cartilage.
- B. In the center of the thyroid cartilage.
- B. In the area of the ligament between the thyroid and cricoid cartilages.
- G. In the area of the trachea below the cricoid cartilage.

16. Is it possible to perform the triple Safar maneuver if there is a suspicion of a cervical spine injury:

- A. Yes.
- B. Sometimes.
- A. No.
- G. All answers are correct.

17. What is the "gold standard" to provide airway patency:

- A. Insertion of an OPA or NPA.
- B. Insertion of an ETT with cuff.
- B. Insertion of a supraglottic airway.
- G. Needle cricothyrotomy.

18. After endotracheal intubation if you see that the patient's condition is worsening, then the possible reasons for this condition are:

- A. Possible failure of breathing equipment.
- B. Kinking or obstruction of the ETT is possible.
- B. Pneumothorax is possible.
- G. All answers are correct.

19. The risk of aspiration pneumonitis in a patient with a "full stomach" can be reduced with the following methods:

- A. Perform rapid sequence intubation using the Sellick maneuver.
- B. Administer antacids prior to intubation, if possible.
- B. Perform gastric lavage before intubation with NG tube, if time permits.
- G. All answers are correct.

20. Indications for tracheal intubation at the prehospital level are the following, except:

- A. Decreased level of consciousness due to alcohol intoxication.
- B. Significant impairment of the level of consciousness as a result of drug intoxication.
- B. Rapidly progressing respiratory failure regardless of the cause.
- B. Cardiac and respiratory arrest.

### Bibliography:

1. Adams H.-A., Fleming A., Friedrich L., Ruschulte H. Atlas of emergency care, Moscow, MEDPress-inform, 2009, p.38-49.
2. Dobson M.B., Anaesthesia in the district hospital. WHO, Geneva, 1989, p. 13-22.
3. Caterino J. M., Kahan S. Emergency Medicine, 2nd edition, Moscow, MEDpress-inform, 2008, p. 300.
4. Kurepina M.M., Ozhigova A.P., Nikitina A.A. Human anatomy, Atlas. Manual for universities, Moscow, Humanitarian Publishing Center "Vlados", 2007, p. 162-164.
5. Rever N., Thiel H., Atlas of Anesthesiology (Translated from German), Moscow, MEDpress-inform, 2009, p. 120-135.
6. Robinson N., Hall J. Anesthesiology Sine qua non: how an anesthesiologist can survive and save the patient's life. Moscow, Binom Publishing House, 2008, p.10-31.
7. Stone J., Fawcett W. Visual anesthesiology. (Translated from English), Moscow, Publishing group "GEOTAR-Media", 2016, p. 19-21.
8. Anesthesiology and Resuscitation edited by V.D. Malyshev, S.V. Sviridov, Moscow, Meditsina, 2003, p. 172-176.
9. Fundamentals of Anesthesiology and Resuscitation. Textbook for Medical Universities. Edited by professor Y.S.Polushin, N-L Publishing House, St. Petersburg, 2014.
10. Essentials of Major Trauma Care. Fourth edition, edited by Skinner and Driscoll, International Committee of the Red Cross. 2013, p.15-20.
11. BLS for Healthcare Provider, American Heart Association; USA, 2011, p. 7-19.
12. CPR Pro for the professional rescuer; American Safety and Health Institute, USA, 2016.

13. Ellis H., Feldman S., Harrop-Griffiths W. Anatomy for Anaesthetists. Eighth edition, UK, Blackwell Publishing, 2004.
14. Kloeck WGJ, A Guide to the Management of Common Medical Emergencies in Adults. Ed.: Division of Emergency Medicine, Faculty of Health Sciences, University of Witwatersrand, Republic of South Africa, Ninth Edition, 2012, p.10-12.

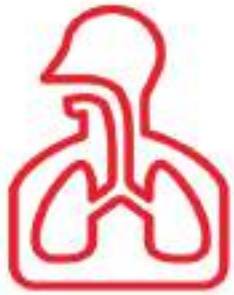List of Internet resources:

1. [www.i-gel.ru](http://www.i-gel.ru)
2. [www.heart.org](http://www.heart.org)
3. [www.intersurgical.ru](http://www.intersurgical.ru)
4. [www.erc.org](http://www.erc.org)
5. [www.ashinstitute.org](http://www.ashinstitute.org)
6. [www.advancedlifesupport.co.za](http://www.advancedlifesupport.co.za)
7. [www.rusnrc.com](http://www.rusnrc.com)

**Correct answers to the tests:**

1. B; 2. C; 3. C; 4. A; 5. A; 6. C; 7. A; 8. A; 9. B; 10. C; 11. A; 12. C; 13. C; 14. C; 15. B; 16. C; 17. B; 18. C; 19. C; 20. A.

# "Mastering Airway Management - A Life-Saving Skill"



**This essential guide covers critical airway management techniques, from the Safar maneuver to endotracheal intubation, equipping healthcare professionals with the knowledge to act decisively in emergencies. A must-read for medical students, emergency responders, and critical care specialists.**

